

Optimizing Anterior Esthetics: Combining Porcelain and Periodontal Considerations in Single-Tooth Replacement: A Case Report

NELSON Y. HOWARD, DDS*

For many years, the only way to permanently replace a single missing tooth with adjacent abutment teeth was with a fixed full- or partial-coverage bridge. This treatment method is generally accepted as the standard of care in dentistry and exhibits durability, long-term function, and strength. Then came the age of the traditional "Maryland bridge," a more conservative treatment modality to replace a missing tooth when compared to a conventional porcelain-fused-to-metal or gold bridge. Limitations of the Maryland bridge include less than optimum esthetics, owing to the underlying metal substructure radiating through the abutment teeth, and difficulty of bonding to metal. Debonding has frequently occurred at the metal-resin interface, because of inadequate micromechanical retention of the resin cements to the oxide on the etched metal framework. Recent improvements in adhesive technology have reduced the incidence of debonding associated with the metal-tooth

interface.¹ The modified Maryland bridge, or fiber-reinforced composite resin bridge, was developed as a way to eliminate some of the drawbacks of the traditional Maryland bridge. The addition of an ultrahigh molecular weight polyethylene fiber (Ribbond, Seattle, Washington) to the tooth-colored composite matrix framework has significantly improved the strength of the bridge against the forces of occlusion. A porcelain veneer is bonded to the reinforced composite framework to achieve the desired esthetics. Significant advances in dental implant therapy have provided another avenue for clinicians and patients whereby a single implant fixture is surgically placed then restored without involving the adjacent teeth. As long as there is adequate pontic space for the dental implant, this treatment modality represents the ideal way to help maintain and preserve the alveolar bone in the extraction site as well as to eliminate the need to use the adjacent or abutment teeth for support of the replacement tooth.

The focus of this article is the use of an ultraconservative, lingually bonded In-Ceram® (Vident, Baldwin Park, California) bridge in the single-tooth replacement of an upper right lateral incisor. This technique was combined with periodontal considerations to create an esthetic ovate pontic site, resulting in an optimal esthetic final result.

MATERIAL SELECTION

In-Ceram was considered the restorative material of choice for several reasons: unprecedented flexural strength (for an all-ceramic system), optimal marginal fit, three-dimensional color and translucency, no metal show-through, excellent esthetics and periodontal tissue biocompatibility, and no thermal sensitivity.²

PATIENT SELECTION

A 24-year-old woman presented on an after-hours emergency basis because of a broken acrylic stayplate replacing her upper right lateral incisor (Figure 1). As a result, the patient was extremely concerned

*Private practice, San Marcos, California

Optimizing Anterior Esthetics: Combining Porcelain and Periodontal Considerations in Single-Tooth Replacement: A Case Report

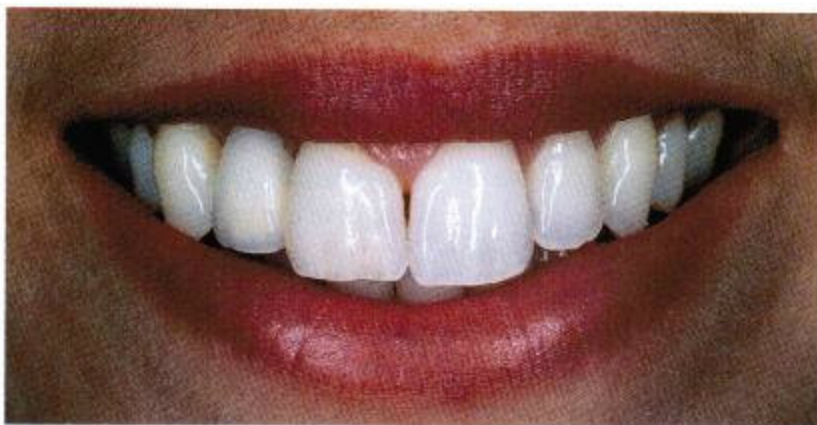

Figure 12. Final smile.

long-term reliability. In-Ceram's proven strength made it the material of choice.⁹

Third, the natural beauty of the abutment teeth was of particular concern. If these teeth were prepared for full-coverage restorations, would the laboratory be able to duplicate their appearance, to match the contralateral teeth? A more conservative and tooth-colored restoration, which was adhered to the lingual surface of the abutment teeth, was necessary to preserve the natural color and esthetics of these teeth. This way, only the pontic restoration would have to be duplicated to the contralateral tooth.

Fourth, the gingival contours of the pontic site were of concern, because if the pontic site was not recontoured prior to the final pontic restoration, a saddle-type pontic would have to be placed, to give the appearance

of a natural emergence profile from the gingiva. A saddle-type pontic design would be less ideal, not only from a hygienic standpoint but also from an esthetic standpoint, as

compared to an ovate pontic site and design.

Fifth, the properties of the adhesive agent to securely bond the partial-coverage restoration to the abutment teeth were analyzed prior to the preparation stage of the restorative procedure. If the restoration was to succeed long-term, the preparation design was critical to provide maximum surface area for retention and adhesion by the luting agent.

Because all these concerns were evaluated in advance, the final result demonstrates outstanding esthetics and a mirror-image effect to the patient's upper left lateral incisor.



Figure 13. Final appearance of a happy patient.

CONCLUSION

With the ever increasing demands from patients for natural and true-to-life esthetic restorations, it is imperative that today's clinician be able to offer treatment options based on the most current technology available. With numerous cosmetic restorative systems presently in use, it is even more important that dentists and laboratory technicians both have a thorough understanding of the various systems before they are actually incorporated into a patient's treatment plan. Careful pre-treatment analysis of the patient's condition is mandatory to achieve the optimal esthetic result. This is especially true when the area of concern is in the anterior segment of the mouth—the most visible to the patient.

The preceding article describes the detailed progression of a multifaceted, highly esthetic, and material-selective case. When all factors influencing the desired outcome are initially addressed and systematically treated, the end result will be most rewarding, enabling the patient to enjoy life with confidence because of the improved smile.

FINAL NOTES

Most recently, the introduction of the Targis-Vectris™ system (Ivoclar North America, Amherst, New York) in the dental marketplace has dramatically improved the technological advances in the areas of conservative, acid-etched, and resin-bonded nonmetallic bridges and further expanded the options for patients when it comes to single-tooth or multiple-teeth replacement.

Although the use of In-Ceram in the Maryland-type bridge has not been clinically proven successful over the long-term, both the author and the patient agreed it was the best esthetic restorative option at the time, given the complexity of the patient's existing dental condition and the limitations of the available restorative materials.

ACKNOWLEDGMENT

The author thanks Shawna Trimble for her patience and cooperation in this restorative procedure.

REFERENCES

1. Rudz GM. Beyond the Maryland bridge. *AACD J* 1996; 12:18-22.
2. Sorensen JA, Torres TJ, Kang SK, Avera SP. Marginal fidelity of ceramic crowns with different margin designs. *J Dent Res* 1990; 69:279-285.
3. Elias JD. Ovate pontics to create interdental papilla. Presented at the American Academy of Cosmetic Dentistry 12th Annual Scientific Session, San Diego, CA, May 1-5, 1996.
4. Dickerson W. A conservative alternate to single-tooth replacement: a three-year follow-up. *Pract Periodont Aesthet Dent* 1993; 5:43-48.
5. Garber D. The edentulous ridge in fixed prosthodontics. *Compendium* 1981; 2:10-21.
6. Miller MB. Aesthetic anterior reconstruction using a combined periodontal/restorative approach. *Pract Periodont Aesthet Dent* 1993; 5:33-40.
7. Howard NY. The ultimate aesthetic challenge: the restoration of a single central incisor. *AACD J* 1997; Winter:24-32.
8. Giordano RA. Dental ceramic restorative systems. *Compendium* 1996; 17:779-794.
9. In-Ceram technique manual. Germany, Vita Zahnfabrik.
10. Ferrari M, Cagidiaco MC, Kugel G. All-ceramic fixed restorations: a preliminary clinical evaluation. *Pract Periodont Aesthet Dent* 1996; 8:73-80.
11. Levy II, Daniel X. Working with the In-Ceram porcelain system. *Prothese Dentaire* 1990; 44:1-11.
12. Kern M, Thompson VP. Bonding to glass-infiltrated alumina ceramic: adhesive methods and their durability. *J Prosthet Dent* 1995; 73:240-249.

Reprint requests: Nelson Y. Howard, DDS, 1903 W. San Marcos Blvd., Suite 110, San Marcos, CA 92069

©1997 Decker Periodicals

Optimizing Anterior Esthetics: Combining Porcelain and Periodontal Considerations in Single-Tooth Replacement: A Case Report



Figure 1. Initial appearance of the patient.

The options included:

1. Single implant fixture and crown to replace her upper right lateral incisor.
2. Composite resin matrix-polyethylene fiber reinforced Maryland-type bridge from her upper right cuspid to the right central incisor with an overlying porcelain veneer bonded over the matrix pontic area.
3. An all-ceramic Maryland-type bridge from her upper right cuspid to the right central incisor with the ceramic framework and pontic tooth fabricated together as a one-piece structure.

about her appearance and wanted a more permanent solution to her “temporary” stayplate. The patient stated that she was scheduled to have a conventional porcelain-fused-to-metal bridge from her upper right cuspid to her right central incisor prepared in 3 days, at a local dental clinic. Because she could not contact the clinic for this after-hours emergency, her husband had contacted my office. After repairing the stayplate (Figure 2), several options for a more conservative and esthetic form of treatment were discussed with the patient based on an evaluation of her smile (Figure 3) and the occlusal relationships present in her mouth (Figure 4).



Figure 2. Appearance after stayplate repaired.

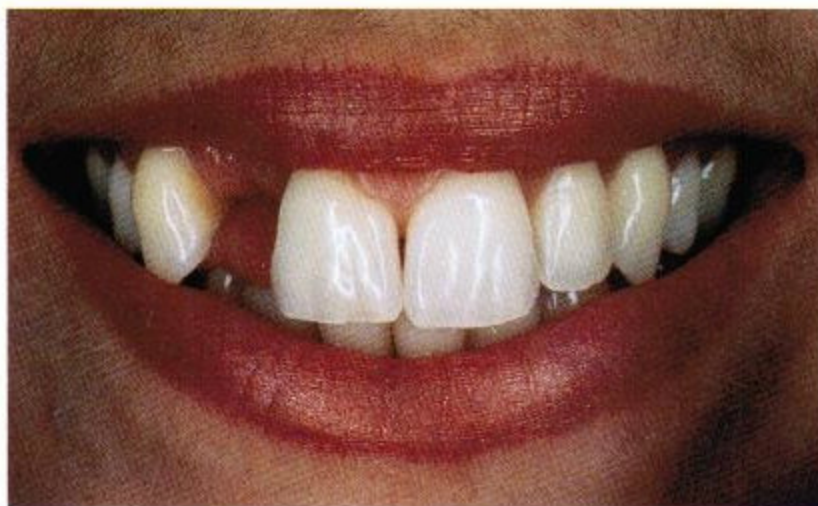

Figure 3. Close-up of patient's existing smile.

Further analysis of the pontic site revealed a less than ideal gingival ridge form (Figure 5), which if not addressed, would result in a pontic with a "saddle-type" design on the underside of the pontic where it contacts the gingival ridge. The preferred gingival pontic design to harmoniously blend esthetics, optimal access for oral hygiene, and periodontal health is the ovate pontic design.³⁻⁶ An esthetic gingival disharmony was also noted on the facial marginal gingiva of her upper right central incisor compared to her upper left central incisor. This was due to a concavity in the root surface at the mesiofacial aspect, resulting in a slight overgrowth and asymmetry of tissue compared to her contralateral tooth. In addition, the patient also presented with

approximately 4 mm of facial recession on her upper right cuspid, which was asymptomatic to sensi-

tivity. This area of recession, if left untreated, would severely compromise both the esthetics and surrounding periodontal health of her upper right cuspid if any type of full-coverage fixed bridge was fabricated and placed for this restorative treatment.

After discussing the treatment options with the patient and educating her regarding the advantages and disadvantages of each restorative procedure (as well as her previously planned porcelain-fused-to-metal bridge), a treatment plan was determined. The patient opted for the one-piece all-ceramic Maryland-type bridge in combination with electrosurgical periodontal recontouring to achieve an ovate gingival

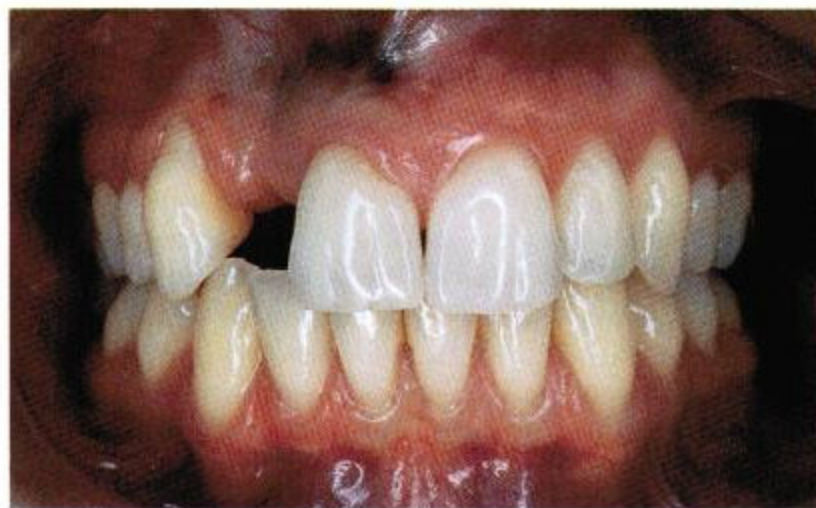

Figure 4. Retracted direct facial view of the patient's condition.

Optimizing Anterior Esthetics: Combining Porcelain and Periodontal Considerations in Single-Tooth Replacement: A Case Report

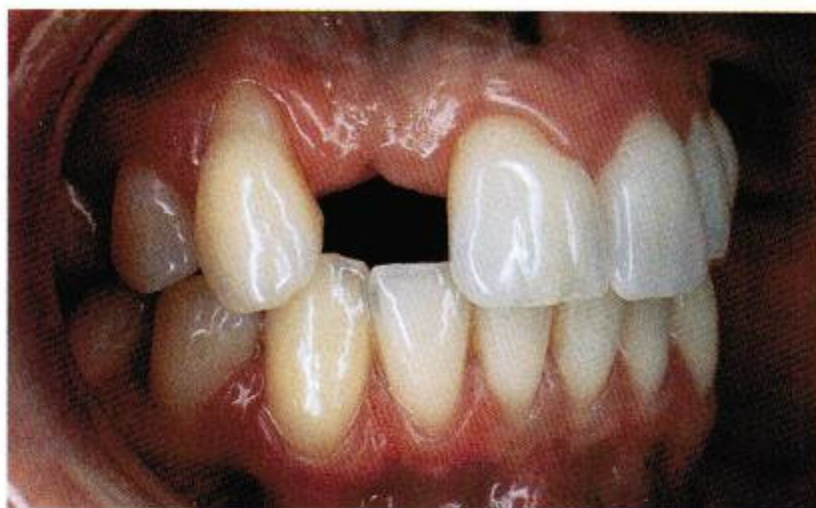

Figure 5. Right lateral view of the patient's condition illustrating the abnormal gingival ridge form.

pontic site and a resculpting of the facial gingiva on her upper right central incisor to harmonize with her upper left central incisor. The patient did not want to have the gingival grafting procedure performed on her upper right cuspid to optimize the overall esthetic outcome. The appearance of this tooth did not bother or concern her at the time, but she would consider the procedure at a later date. The gingival appearance of her upper right central incisor was also not a concern to the patient. Her main concern was to permanently replace her lateral incisor as quickly as possible. The patient did not desire periodontal surgery for her upper right cuspid or dental implant surgery. She had experienced numerous endodontic and oral surgeries in an attempt to save her

lateral incisor from eventual extraction and was simply "burned out" from all the previous procedures.

The patient had expressed a strong desire to lighten her teeth prior to the final restoration. The initial phase of the patient's treatment consisted of the fabrication of custom bleaching trays from maxillary and mandibular alginate impressions. The material selected to lighten or bleach the patient's teeth was Life•Like 10% (Life•Like Dental Products, Santa Barbara, California). The author has used this material with numerous patients, and the incidence of sensitivity or failure to lighten is less than 0.05%. The patient was instructed to use the bleaching gel for a maximum of 3 hours per day according to the manufacturer's instructions. The

desired level of bleaching or lightening was achieved in 2 weeks.⁷ The patient was then scheduled for the periodontal aspect of her treatment.

PERIODONTAL PHASE OF THERAPY

After infiltration with local anesthetic, electrosurgical resculpting of the facial marginal gingiva on the upper right central incisor was achieved to match the upper left central incisor. Because of the extreme concavity at the mesio-facial aspect of the root structure on the upper right central incisor, the patient was informed that gingival regrowth might occur and that more definitive periodontal procedures may be necessary at a later date to permanently correct the gingival disharmony.

Prior to initiation of the ovate pontic site recontouring, the gingival-most height and position of the future pontic was located. Using a clear millimeter ruler, a line was drawn from the highest point of the facial gingiva on her upper left cuspid to the same point of reference on the upper left central incisor. The location of the highest point of the facial gingiva on her upper left lateral incisor was measured to this reference line and noted. The identical line from her upper right cuspid to right central incisor was drawn and the position of the facial gingiva of her upper left lateral incisor with respect to the line from the upper left central incisor to left cuspid was transferred to the patient's gingival tissue and marked by a periodontal probe punch. Since both the facial gingival height of the upper central incisors as well as the incisal to cemento-enamel junction (CEJ) length on both upper cuspids were the same, this point of reference served as a guide from which to begin the ovate pontic site recontouring. The ovate pontic site was carefully recontoured with a large round electro-surgical tip, to achieve the ideal site form. Upon completion of the ovate pontic site, the underside of the pontic on the patient's stayplate was modified with a fast-setting acrylic to maintain the soft tissue ovate pontic morphology. Oral hygiene instructions were given to the patient and the area was allowed to heal for 1 week. The final

ovate pontic site seen in Figure 6 shows excellent healing and tissue response, with a relapse of the facial gingival form on the upper right central incisor, as expected.

PREPARATION APPOINTMENT

Initial shade selection, using the Vita Lumin Shade Guide (Vita Zahnfabrik, Bad Sackingen, Germany) was confirmed and color-mapping was performed so that the laboratory could reproduce the desired shade identical to her upper left lateral incisor. Local anesthetic was given for patient comfort and the lingual aspects of the upper right cuspid and central incisor were prepared with two diamond burs, No. 6878 and No. 6847, and one carbide bur, No. 170L (Brasseler, Savannah, Georgia). The minimal thickness of the framework coping for In-Ceram is approximately 0.5 mm and the pontic joints should be as thick as

possible.⁸ Because of the opposing occlusion contact scheme, as well as the thickness of the enamel on both teeth, the preparation depths achieved were 1.25 mm to 1.50 mm, to provide for maximum strength. The margins were prepared as a shoulder with rounded axial-cervical line angles. All preparation margins were kept supragingival and the lingual aspect of each tooth was prepared, to maximize the pontic joint strength and thickness. The interproximal facial preparation margins on either side of the pontic space were kept to just short of the ideal contact area. This would allow the interproximal contact areas of the final restoration to contact the adjacent abutment teeth at the ideal position, not too facial or too lingual. The final preparations are shown in Figure 7.

Final impressions were taken using a polyether material (Impregum,

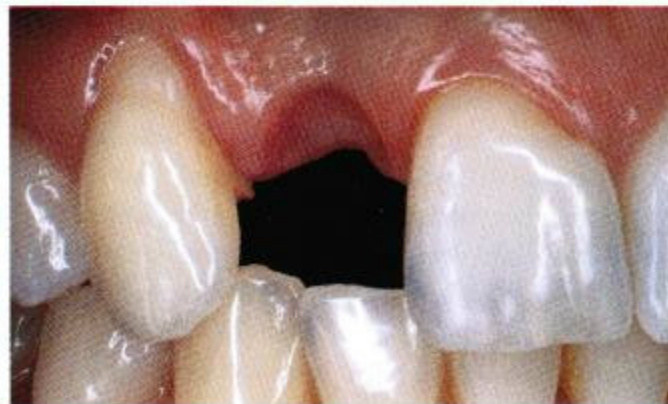

Figure 6. Close-up view of the recontoured ovate pontic site.

Optimizing Anterior Esthetics: Combining Porcelain and Periodontal Considerations in Single-Tooth Replacement: A Case Report

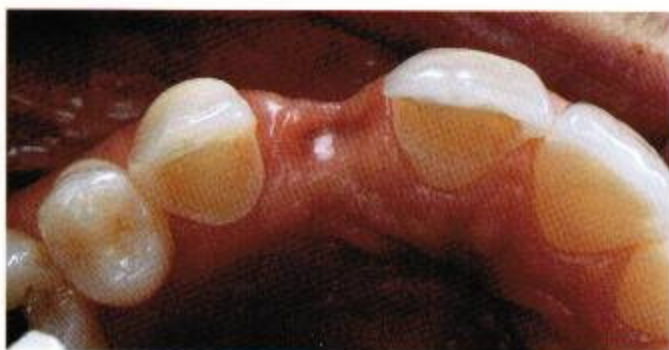

Figure 7. Occlusal view of the final bridge preparations.

Espe-America, Norristown, Pennsylvania). A lower alginate impression was taken for the opposing model, and a bite registration was taken (Regisil PB, Dentsply Caulk, Milford, Delaware). No temporization was necessary since the entire preparation was kept within the enamel structure. The patient was comfortable and experienced no postoperative discomfort.

LABORATORY FABRICATION

The In-Ceram fabrication is a two-stage technique. The first step uses an extremely fine-grained aluminum oxide powder suspension in a slip-casting procedure to create a core material for crowns and fixed bridges. The powder slip suspension is applied to the plaster die, which absorbs the moisture immediately, causing an almost dry and densely packed material layer to form on the die. This layer can be modeled with a scalpel to the required form. During sintering, the die shrinks

and can be removed in one piece from the substructure. Since sintering of the slip-casting aluminum has only been initiated during firing (i.e., the particles have just begun to stick lightly together), shrinkage of the substructure is virtually impossible. This allows a perfect fit of the substructure onto the master die that remains intact on further firing.⁹ The final substructure (framework core) is seen in Figure 8. The actual clinical try-in of the substructure is seen in Figure 9. The marginal accuracy is then checked.

The second step is the infiltration firing step. The outer surfaces of the porous, sintered substructure are coated with a slurry of glass powder and fired at 1100°C. By means of this infiltration firing process, the sintered substructure is infused with molten glass, which results in a fine-grained substructure with an optimal glass matrix. Crack propagation is limited, owing to the

densely stacked aluminum particles. The different thermal expansion coefficients of glass and aluminum serve to increase the strength and limit crack propagation. Thus, this homogenous, bubble-free substructure is responsible for the high stability and elevated bond strength of the restoration compared to other currently used dental ceramics.¹⁰ Any surplus glass particles remaining on the substructure after the infiltration firing are removed by grinding or air-abrasion.⁹

After the coping has been completed and the marginal integrity clinically verified, the porcelain application is initiated. For full-coverage restorations, the marginal fit is achieved during the first firing and is retained throughout the entire procedure, despite repeated firings.¹¹ The retention of the marginal fit is due to the fact that the subsequent porcelain firings are carried out 200°C below the temperature of the initial firing.¹⁰ Vita-Dur-α[®] porcelain was used to recreate the desired esthetics necessary for the final restoration of her upper right lateral incisor but was not applied to the abutment "wings" since the ideal shape and thickness of the abutment wings was achieved with the framework core material. Upon completion of the porcelain application, the final restoration was ready for clinical evaluation to assess overall esthetics, contours, occlusion, and symmetry to the contralateral side (Figure 10).

CEMENTATION PROCEDURE

The manufacturer recommends either a zinc phosphate cement or a glass ionomer cement as a luting agent for In-Ceram crowns and bridges. Panavia® (J. Morita USA/Kuraray, Tustin, California), a self-curing resin cement, has been shown to bond well with In-Ceram, which cannot be easily etched,¹² especially with inlay and partial-coverage restorations.⁹ For the cementation process of this partial-coverage restoration, Panavia was selected as the cement of choice because of its exceptional strength and adhesive properties.

After the clinical try-in was completed, the abutment wings of the In-Ceram bridge were rinsed with water, air-dried, then etched for 60 seconds with 35% phosphoric acid (Ultraetch, Ultradent Products, South Jordan, Utah). The main purpose of the etchant was to clean the internal surface of the wings for eventual adhesion to the tooth structure. The wings were then rinsed and air-dried, and the bridge set aside. Rubber dam isolation of the abutment teeth was placed, and the prepared tooth surfaces were pumiced with a medium-grain pumice and water mixture. The teeth were rinsed, air-dried, then etched for 30 seconds with 35%

phosphoric acid, then rinsed again with water for 60 seconds and air-dried. The main purpose of the etchant on the prepared tooth surfaces was to remove any surface contaminants that might interfere with the adhesion of the Panavia cement to the In-Ceram bridge.

The Panavia cement was mixed according to the manufacturer's instructions and applied to the internal surface of the wings and to the prepared teeth surfaces. The In-Ceram bridge was then placed into position and excess cement was removed with a rubber-tipped instrument (Gum Stimulator, J.O. Butler, Inc., Chicago, Illinois). Since

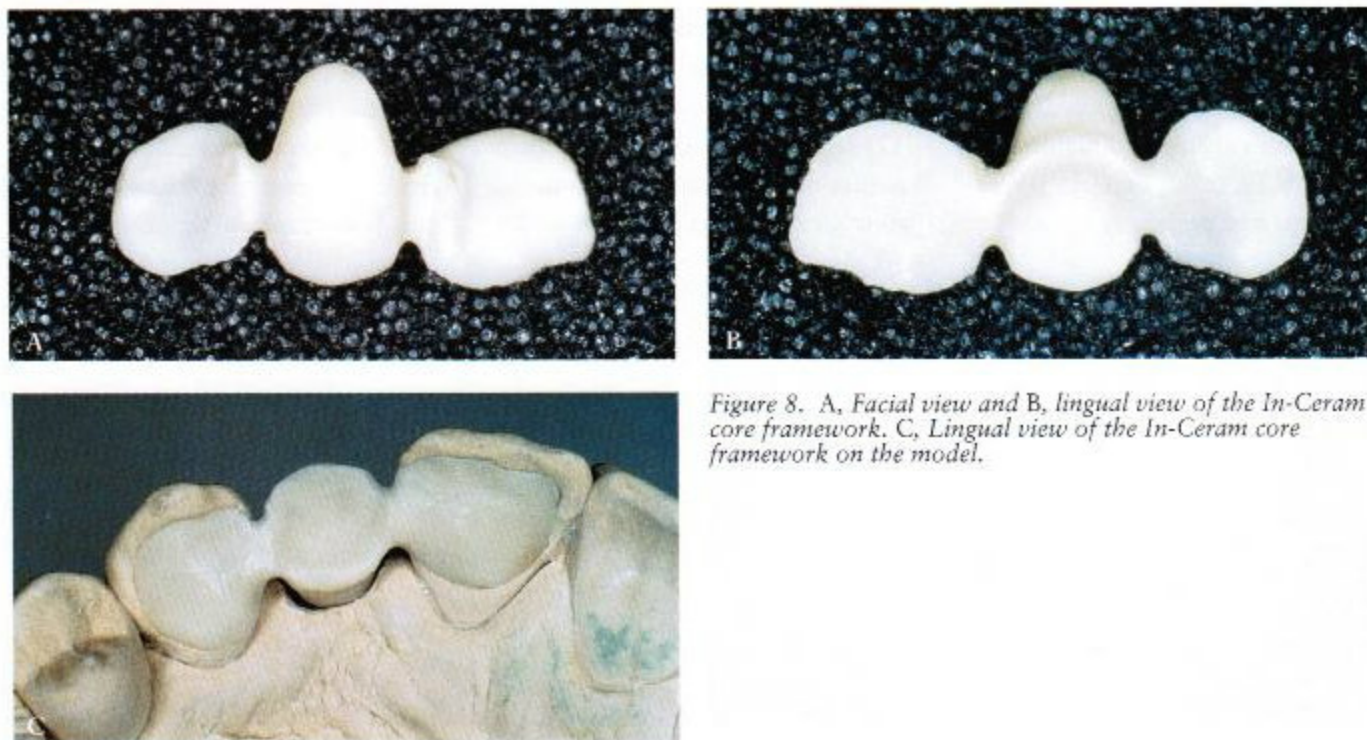


Figure 8. A, Facial view and B, lingual view of the In-Ceram core framework. C, Lingual view of the In-Ceram core framework on the model.

Optimizing Anterior Esthetics: Combining Porcelain and Periodontal Considerations in Single-Tooth Replacement: A Case Report

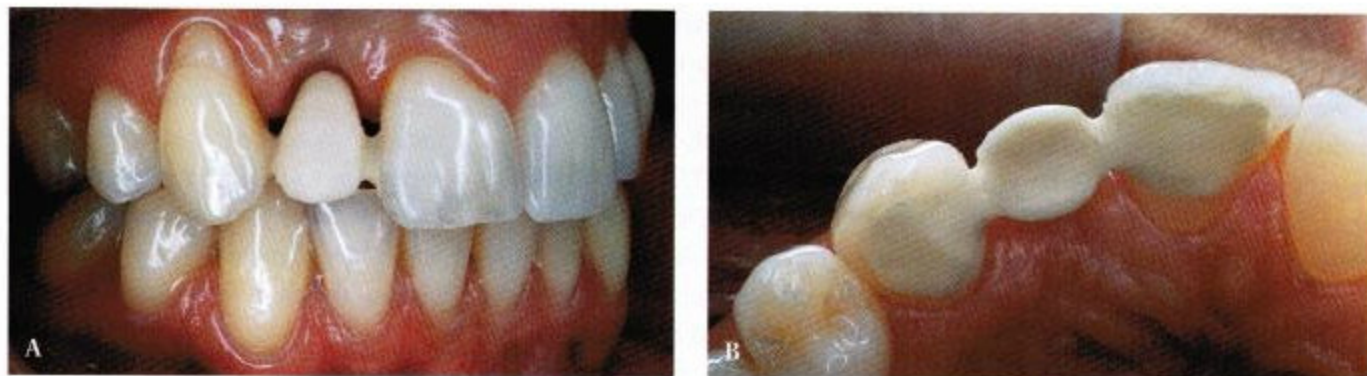


Figure 9. A, Facial view of the In-Ceram framework at the try-in stage. Note how the pontic extends from the ovate pontic site. B, Lingual view.

Panavia will not set in the presence of oxygen, Oxyguard (included in the Panavia kit) was applied to the restoration margins for the cement to set completely. After the appropriate setting time, the Oxyguard and rubber dam were removed. The occlusion, laterotrusion, and protrusive movements were checked and adjusted. Final finishing in the traditional manner was completed using fine carbide and diamond finishing burs, then porcelain polishing cups and points.

The final restoration, shown in Figure 11, demonstrates excellent esthetic harmony as well as uniform balance and symmetry to the contralateral side. The perfect emergence profile of the pontic restoration from the gingival ridge is a direct result of the proper use of the ovate pontic and site design as previously discussed. The patient was extremely pleased with her new smile (Figure 12) and with the ultraconservative nature of her treatment, compared to what she might have had with a

conventional porcelain-fused-to-metal bridge. Her facial appearance clearly expressed her happiness with this highly advanced esthetic procedure (Figure 13).

DISCUSSION

Achieving optimal esthetics in any treatment modality necessitates the clinician's awareness of many aspects. This is even more apparent when the area of concern is in the anterior segment of the mouth. Not only is it important that the clinician

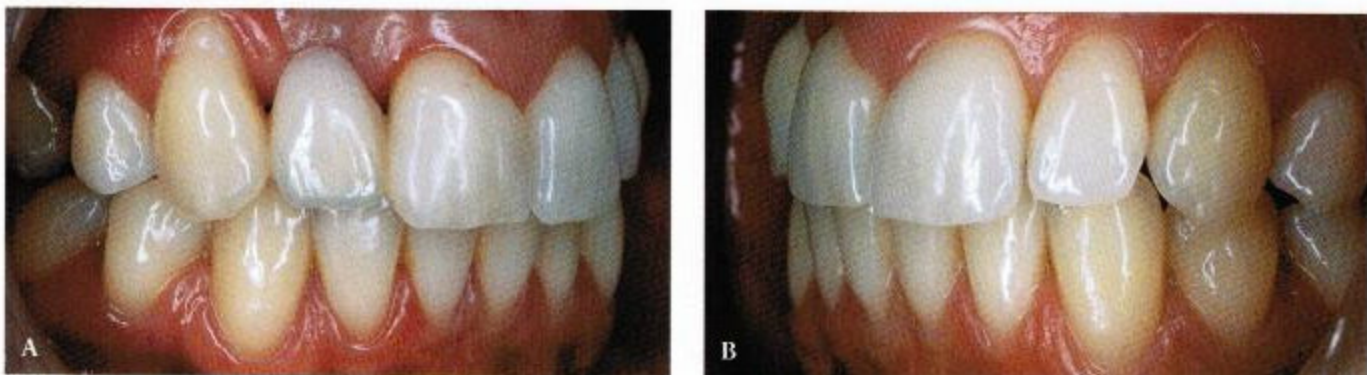

Figure 10. A, Right lateral view of the final bridge at the try-in stage. B, Left lateral view of the adjacent dentition for comparison.

have a diverse knowledge of the dental materials and products currently available, but that he or she be able to properly use them for the particular restorative situation.

The restorative case presented here illustrates several areas of concern that were addressed prior to beginning the actual restorative procedure. First, the high smile line and the existing facial recession on the upper right cuspid were evaluated. Clinicians desire that patients complete all of the recommended treatment, to ensure the most optimal

end result, especially when it involves the anterior teeth and the smile that will follow. But this expectation is not always met, particularly when financial considerations, time constraints, and patient likes and dislikes become determining and often limiting factors; these factors can often compromise an ideal outcome that is envisioned by the restorative dentist. This is reality, and simply stated, not all patients want what the practitioner wants them to have, even if it is for their best long-term benefit. Because this patient did not want to

undertake a periodontal graft on her upper right cuspid prior to the bridge preparation, a modified, more conservative, and esthetically challenging bridge was necessary to achieve the best overall result.

Second, the strength of the subsequent bridge is an important concern, especially where the opposing dentition occludes and functions against it. An all-ceramic material that possesses better strength and durability than conventional porcelain-fused-to-metal restorations was necessary to provide

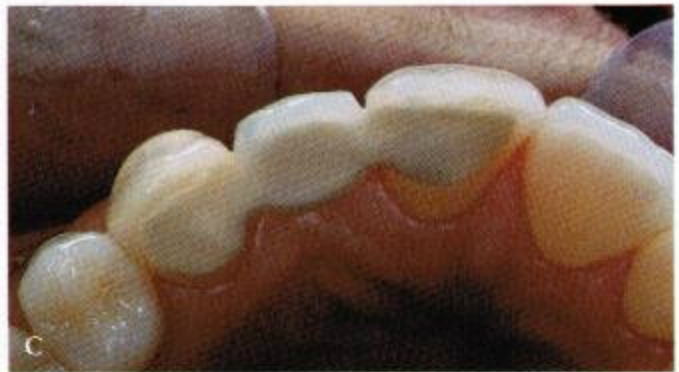
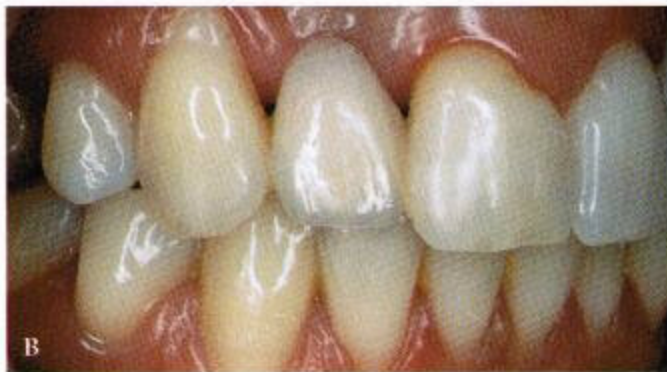
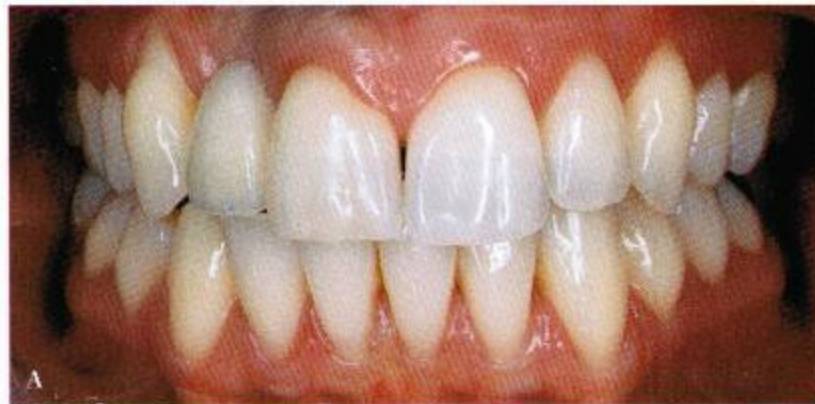
Figure 11. A, Final direct facial view after cementation, demonstrating mirror-image effects to the contralateral incisor. B, Final close-up right lateral view after cementation, showing excellent esthetics and a harmonious emergence profile from the gingiva. C, Final lingual view after cementation.